

A retrospective study of a new *n*-butyl-2-cyanoacrylate glue ablation catheter incorporated with application guiding light for the treatment of venous insufficiency: Twelve-month results

Turhan Yavuz¹ , Altay Nihat Acar¹, Huseyin Aydın² and Evren Ekingen³

Abstract

Objective: This study aims to present the early results of a retrospective study of the use of novel *n*-butyl-2-cyanoacrylate (VenaBlock)-based nontumescent endovenous ablation with a guiding light for the treatment of patients with varicose veins.

Methods: Patients with lower limb venous insufficiency were treated with *n*-butyl-2-cyanoacrylate (VenaBlock Venous Closure System) between April 2016 and July 2016. The study enrolled adults aged 21–70 years with symptomatic moderate to severe varicosities (C2–C4b) and great saphenous vein reflux lasting longer than 0.5 s with great saphenous vein diameter between 5.5 and 15 mm assessed in the standing position. No compression stockings were used after the procedure. Duplex ultrasound imaging and clinical follow-up were performed on the third day, first month, sixth month, and 12th month. Clinical, etiological, anatomical, pathophysiological classification; venous clinical severity score; and completed Aberdeen varicose vein questionnaire were recorded.

Results: Five hundred thirty-eight patients with great saphenous vein incompetency underwent *n*-butyl-2-cyanoacrylate ablation. The mean ablation length was 25.69 ± 4.8 cm, and the average amount of *n*-butyl-2-cyanoacrylate delivered was 0.87 ± 0.15 ml. The mean procedure time was 11.7 ± 4.9 min. Procedural success was 100%, and complete occlusion was observed after treatment and at the third-day follow-up. We observed ecchymosis in five patients (1.00%) at the entry site at the third-day follow-up. Phlebitis was encountered with six (1.20%) patients. No skin pigmentation, hematoma, paresthesia, deep vein thrombosis, or pulmonary embolism was observed. Kaplan–Meier analysis yielded an occlusion rate of 99.4% at the 12-month follow-up. All patients had significant improvement in venous clinical severity score and Aberdeen varicose vein questionnaire scores postoperatively ($p < 0.0001$). Venous clinical severity score scores decreased from 5.43 ± 0.87 to 0.6 ± 0.75 . Aberdeen varicose vein questionnaire scores decreased from 18.32 ± 5.24 to 4.61 ± 1.42 .

Conclusions: The procedure appears to be feasible, safe, and efficient in treating the great majority of incompetent great saphenous veins with this technique.

Keywords

n-Butyl-2-cyanoacrylate ablation, cyanoacrylate ablation, nontumescent endovenous ablation, chronic venous insufficiency, varicose veins

Objective

Primary varicose vein-related problems are progressive medical conditions that affect a significant portion of the community. Treatment methods for chronic venous diseases (CVD) had been varied in the past decade. Previously, surgical treatment methods such as ligation

¹Department of Cardiovascular Surgery, Süleyman Demirel University Faculty of Medicine, Isparta, Turkey

²Department of Radiology, Süleyman Demirel University Faculty of Medicine, Isparta, Turkey

³Batman Regional State Hospital, Batman, Turkey

Corresponding author:

Turhan Yavuz, Süleyman Demirel Üniversitesi Araştırma ve Uygulama Hastanesi, Doğu Yerleşkesi, Isparta 32260, Turkey.

Email: turhan.yavuz@gmail.com

and stripping were the first choice, requiring spinal or general anesthesia within the operating room.

Endovenous thermal ablation techniques (EVTA) (laser and radiofrequency) have been shown to be safe and effective treatments for venous insufficiency with high- and long-term closure rates.¹ Although thermal ablation techniques yield satisfactory results, the necessity of tumescent anesthesia, compression stockings after treatment, side effects such as bruising along the great saphenous vein (GSV), paresthesia, arteriovenous fistula, pseudoaneurysm formation, and other potential side effects can cause severe discomfort for the patient.^{2,3}

To eliminate patient discomfort and the side effects of EVTA, new nonthermal, nontumescent method has been introduced on the market: cyanoacrylate ablation (*n*-butyl-2-cyanoacrylate (NBCA)). NBCA had been used endovenously since 2000 for the treatment of arteriovenous malformations and for gastric and duodenal varicose veins for several decades.^{4,5} Almeida et al.⁶ and Bozkurt and Yilmaz⁷ showed safety and efficiency for two kinds of NBCA and delivery systems for endovenous treatment of GSV reflux. However, the composition of NBCA as well as its application technique is critical in NBCA-based treatments. Because polymerization starts immediately and the technique requires external compression, catheter pullback speed and where to apply compression during the procedure are crucial. Here we used the VenaBlock Venous Closure System (Invamed, Ankara, Turkey), consisting of a proprietary formula of NBCA with dimethyl sulfoxide and a dispensing system (Figure 1). This formula of NBCA polymerizes much faster than other similar products in the market. Therefore, this system requires fast pullback and immediate external manual compression. The catheter has an advanced visibility under ultrasound (USG) and an aiming laser light that can be seen outside that facilitates to locate the tip of the

catheter. Therefore, the purpose of this study was to assess the safety and efficacy of the new VenaBlock NBCA ablation of the GSV.

Methods

Study protocol

In this independent retrospective study, 538 patients with lower limb venous insufficiency were treated between April 2016 and July 2016 in Süleyman Demirel University Faculty of Medicine, Isparta, Turkey by physicians Yavuz, Acar, and Aydın. The study enrolled adults aged 21–70 years with symptomatic moderate to severe varicosities (C2–C4b patients CEAP: Clinical, etiological, anatomical, and pathophysiological classification) and GSV reflux lasting longer than 0.5 s with GSV diameter ≥ 5.5 mm assessed in the standing position. Patients were excluded if they had a history of deep vein thrombosis or pulmonary embolism, reflux of the femoral vein going beyond the knee (high degree of deep vein insufficiency), hemodynamically significant reflux of the small saphenous vein or anterior accessory GSV, symptomatic peripheral arterial disease, or GSV >15 mm. In order to better figure out effects of NBCA in venous valve incompetence and to achieve statistically significant and plain results, we just focused on the patients with GSV insufficiency in this cohort despite the fact that this treatment can also be used in patients with small saphenous vein and accessory vein incompetence as well as concomitant deep vein reflux. Further eligibility criteria are shown in Table 1. Ethical approval was taken from our institutions ethics board with the article number 48. Informed consent was taken from each patient before procedures.

Assessment

After patients' eligibility was confirmed and written informed consent was obtained, the patients underwent a clinical examination by a senior surgeon and USG examination by an independent radiologist. CEAP, venous clinical severity score (VCSS) assessments, and USG results were recorded. In addition, patients were asked to complete a quality of life (QoL) survey based on the Aberdeen varicose vein questionnaire (AVVQ) on the day before the procedure and then one month, six months, and 12 months after the procedure. We used Turkish translated and nonvalidated version of AVVQ. The total score for the 13 questions ranged from 0 to 100 points, with 0 point indicating the best possible QoL.⁸

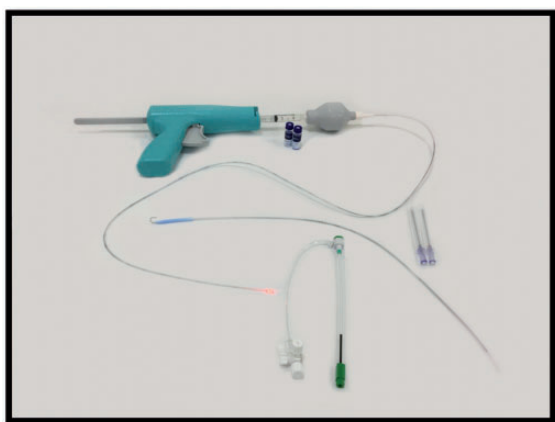


Figure 1. The content of VenaBlock venous closure system.

Table 1. Inclusion and exclusion criteria.**Inclusion criteria**

1. Age ≥ 21 years and ≤ 70 years with symptomatic varicose veins
2. CEAP classification of C2–C4b
3. GSV diameter at the SFJ while standing ≥ 5.5 mm and ≤ 15 mm
4. Reflux in the GSV ≥ 0.5 s, determined by CDUS
5. Ability to walk unassisted
6. Ability to come to follow-up examinations
7. Mentally healthy to approve procedure

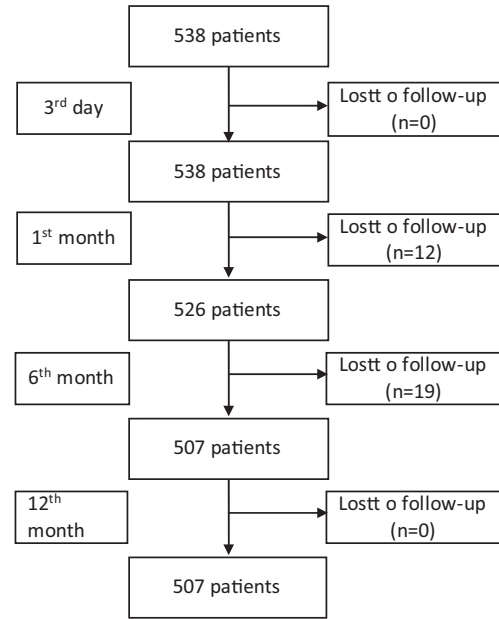
Exclusion criteria

1. Life expectancy < 1 year
2. Cancer
3. DVT history
4. Active thrombophlebitis in deep or superficial veins
5. Arterial insufficiency history or ankle-brachial index < 0.9
6. Significant femoral or popliteal venous insufficiency
7. History of intervention with GSV to be treated
8. Conditions that prevent vein treatment
9. Immobilization
10. Pregnancy
11. Aneurysm of the target vein with local diameter > 15 mm
12. Duplicate or accessory GSV with venous insufficiency
13. Known sensitivity to cyanoacrylate adhesives
14. Advanced tortuous GSV

CDUS: color Doppler ultrasonography; CEAP: clinical, etiology, anatomy, and pathophysiology classification; DVT: deep vein thrombosis; GSV: great saphenous vein.

VenaBlock procedure

All procedures were performed under local anesthesia with standard sterile technique. The GSV was accessed percutaneously with a 6 French sheath. The catheter was advanced through an introducer sheath without a guidewire and without a long introducer catheter. After turning on a light switch on the VenaBlock catheter, it was advanced through the GSV and placed 3 cm away from the saphenofemoral junction (SFJ). After the catheter position was confirmed, the operating table was set to the supine position to minimize blood flow in the GSV. Every 5 s push on the gun trigger delivered 0.3 ml NBCA with a pullback rate of 2 cm/s applied on every 10 cm until the vein segment was fully supplied with NBCA. At the end, 0.03 ml of NBCA would be applied on every centimeter. This procedure was repeated for every 10 cm of GSV. At the end, the catheter and the sheath were removed and manual compression was applied on the puncture site. Occlusion of the GSV was confirmed with ultrasonographic evaluation during the procedure (Figure 2). If there was any unoccluded segment, the procedure was repeated through separate access. We did not perform phlebectomy or sclerotherapy in the same session as saphenous

**Figure 2.** Flowchart.

ablation. We waited for three to six months, and then we performed phlebectomy or sclerotherapy as needed. After the procedure, the patients were rated for procedural pain on a scale of 1–10 (10 extreme pain, 0 no pain). In addition, the patients were asked to evaluate any burning sensation in their legs during the procedure. No compression stockings were used after the procedure.

Follow-up

Follow-up visits were performed at the third day, first month, sixth month, and 12th month. At each visit, an independent USG study and a clinical examination were performed. Treatment success was defined as complete occlusion of the treated GSV. Any patency or recanalization, reflux, or open segment > 5 cm in length was considered a failure.^{9,10}

Statistical analysis

Complete closure of the GSV was calculated using Kaplan–Meier methods. Changes from baseline in VCSS and AVVQ were compared between control periods by repeated measure analysis of variance and paired *t*-test. Values are expressed as mean \pm standard deviation or number and percentage (*n*, %). All statistical comparisons were made using the SPSS version 22 statistical package.

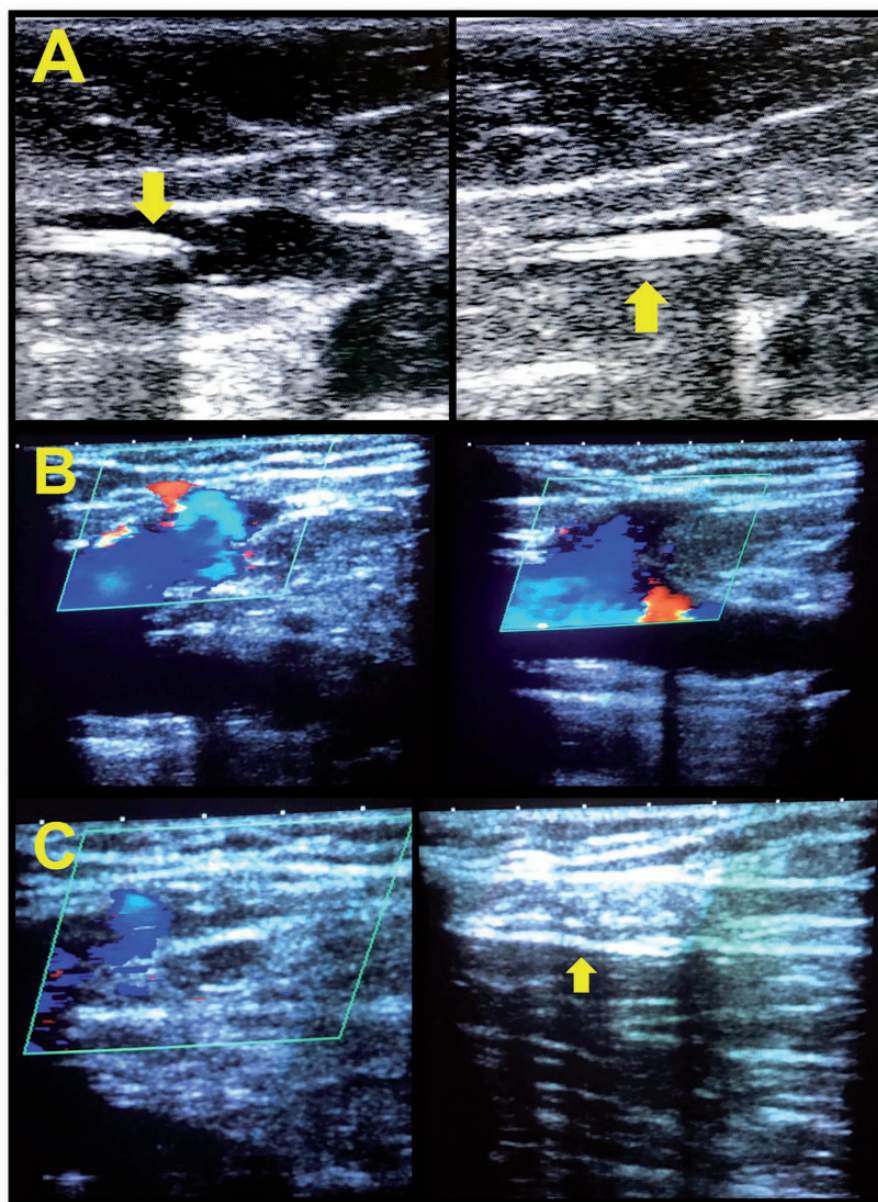


Figure 3. USG images of incompetent GSV (a) NBCA; VenaBlock catheter at SFJ, (b) after treatment with NBCA, and (c) color Doppler of SFJ after treatment.

Results

A total of 538 patients aged 21–70 years with lower extremity venous insufficiency were enrolled in the study. Thirty-one patients were lost to follow-up (11 patients at the first month, 20 patients at the sixth month), and their data excluded from the study, which resulted in analysis of 507 patients' data in total (Figure 3). Patients (360 women (67%)) were a mean age of 44.6 ± 10.1 (range 21–70 years). By the CEAP classification, 176 patients (33%) were C₂, 339 (63%) were C₃, and 23 (4%) were C₄. The average preprocedural VCSS

was 5.4 ± 0.9 (range 4–8). The mean preprocedural diameter of GSV at the SFJ in the standing position was 6.7 ± 1.7 mm (range 5.5–14.6) with a mean reflux of 1.9 ± 0.8 s (range 1–5) (Table 2).

The mean treatment length was 25.7 ± 4.9 cm (range 10–43), and the average NBCA delivered was 0.87 ± 0.15 ml (range 0.4–1.39), which is fully dependent on treated vein length. The mean procedure time was 11.8 ± 4.9 min (range 5–33). The GSV was accessed in 52% of the patients above the knee and 48% above the knee level.

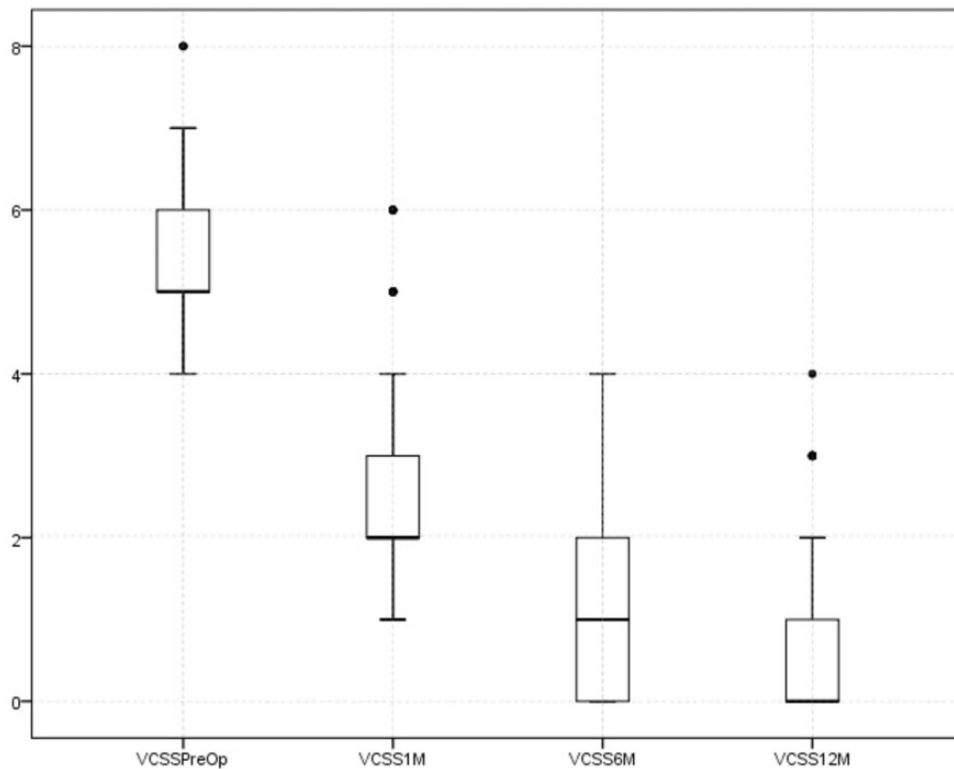


Figure 4. VCSS at baseline and follow-up. VCSS: venous clinical severity score.

Procedural success was 100%, and complete occlusion was observed after treatment and at the third day follow-up. Partial recanalization was observed in two (0.4%) patients at the SFJ over 5 cm at the first month. The six-month follow-up showed the same results as the first month. One total recanalization observed in 12th month follow-up that yielded with a 99.4% complete occlusion rate (Table 4, Figures 4 and 5). We also had five patients using anticoagulant therapy who underwent NBCA application without any bleeding complication or closing failure.

No significant morbidity or mortality was related to the procedure. There was no deep venous thrombosis, pulmonary embolism, or paresthesia. We did not observe the common femoral vein thrombosis or polymerized glue extending to the common femoral vein. In the initial part of our experience, we observed ecchymosis in five patients (1.00%) at the entry site at the third day follow-up.” (Table 3) As we explained in the “Results” section, we thought this ecchymosis was related to applying NBCA to the entry point at the end of the procedure. Therefore, NBCA injection was terminated 2 cm before and from the entry point with help from the guide light for the rest of the patients. No ecchymosis was observed after this procedural change. Phlebitis was encountered with six (1.20%) patients. No skin pigmentation, hematoma, paresthesia, deep

vein thrombosis, or pulmonary embolism was observed.

All patients had significant improvement in VCSS and QoL scores postoperatively.

VCSS scores at preintervention and at 12th month were 5.43 ± 0.8 (range 4–8) and 0.6 ± 0.75 (range 0–4), respectively ($p < 0.0001$) (Table 5). AVVQ scores at preintervention and at 12th month were 18.32 ± 5.2 (range 9–30) and 4.61 ± 1.42 (range 1–8), respectively ($p < 0.0001$).

Discussion

This is the first study analyzing early clinical results of a new NBCA-based saphenous vein ablation system in a substantial number of patients. Results from this study confirm that NBCA is safe and highly effective for the treatment of venous insufficiency. No serious adverse events or toxicological effects were registered during the 12-month follow-up. To date, no toxicological, carcinogenic, or mutagenic effect has been reported for NBCA.^{4,5,11}

Wang et al. showed histopathological changes in the vessel wall after cyanoacrylate injection with a study on adult rabbits. Results showed that after rapid polymerization of the NBCA, acute inflammatory effects were observed in two weeks, then chronic granulomatous

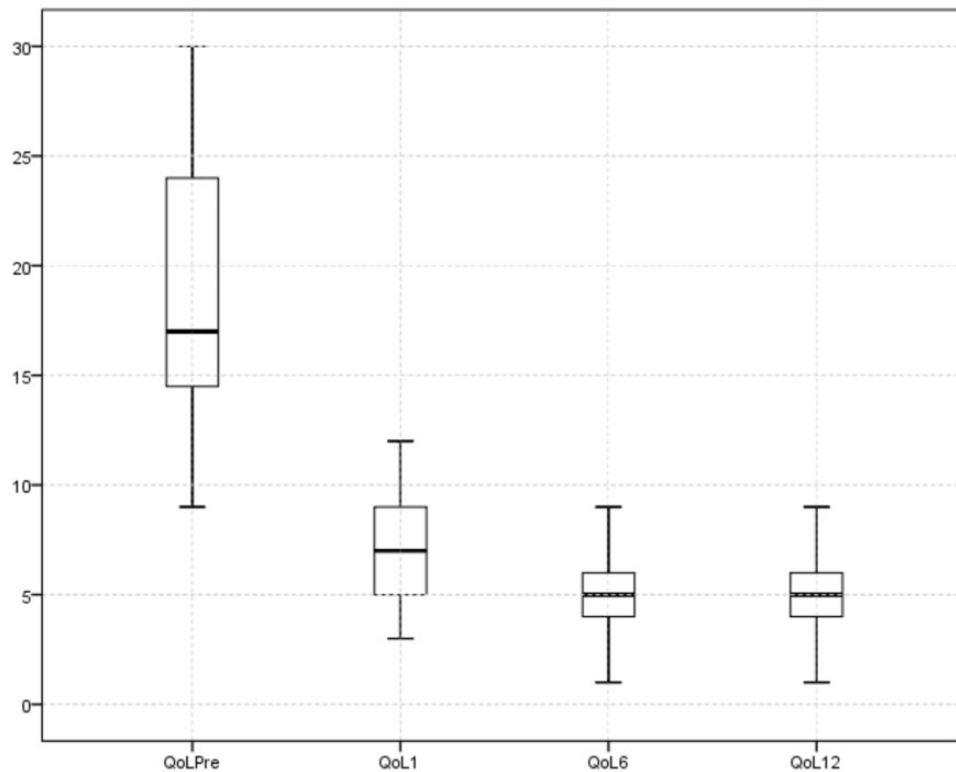


Figure 5. QoL scores at baseline and follow-up. QoL: quality of life.

Table 2. Demographics.

	<i>n</i> = 538	
	Mean ± Std (<i>n</i>)	<i>n</i> (%)
Age (years)	44.56 ± 10.04	
Female gender		360 (67)
Diameter at SFJ (mm)	6.70 ± 1.65	
Reflux at SFJ (s)	1.90 ± 0.81	
CEAP category		
C2		176 (33)
C3		339 (63)
C4		23 (4)
VCSS	5.43 ± 0.87	
AVVQ	18.32 ± 5.24	

AVVQ: Aberdeen varicose vein questionnaire; CEAP: clinical, etiology, anatomy, and pathophysiology classification; SFJ: saphenofemoral junction; VCSS: venous clinical severity score.

foreign body reaction at two months and, finally, fibrosis. Another important point in this study was mainly inflammation without proliferation of elastic fibers in the veins.¹² Almeida et al. showed similar results in a 60-day swine model. After NBCA was injected in the vein, acute inflammation, formation of foreign body giant cells, and granulomas and fibrosis were seen histologically.¹³ Chaloupka et al. identified three phases of polymerization in an explanted swine common carotid

Table 3. Procedure results.

	Mean ± Std (<i>n</i>)	<i>n</i> (%)
Length of treated segment (cm)	25.69 ± 4.88	
Procedure duration (min)	11.75 ± 4.97	
Pain during procedure	2.19 ± 0.94	
Burning sensation		378 (70)
Ecchymosis		5 (0.9)
Skin pigmentation		0 (0)
Phlebitis		6 (1.1)
Paresthesia		0 (0)
DVT		0 (0)
PE		0 (0)

DVT: deep vein thrombosis; PE: pulmonary embolism.

artery model: (1) initial rapid polymerization with increasing tensile forces lasting approximately 10 s; (2) second phase, of nearly constant tensile force, which lasts up to 1 min; and (3) a final phase characterized by a rapid, exponential rise of tensile force that completed polymerization. The polymerization times varied based on the formulation and type of CA and the amount of intravascular blood or saline.¹⁴

In the past five years, there has been an ongoing interest in NBCA-based venous ablation. The first system is application of viscous NBCA in a pulsed technique. Following the validation of NBCA in

Table 4. Closure rates.

	n (%)
Third day	
Total	538 (100)
Partial	0 (0)
Recanalization	0 (0)
First month	
Total	525 (99.6)
Partial	2 (0.4)
Recanalization	0 (0)
Sixth month	
Total	505 (99.6)
Partial	2 (0.4)
Recanalization	0 (0)
Twelfth month	
Total	504 (99.4)
Partial	2 (0.4)
Recanalization	1 (0.2)

Table 5. Clinical assessment.

	Mean±Std (n)
VCSS	
Pre-op	5.43 ± 0.87 (538)
First month	2.43 ± 0.75 (527)
Sixth month	1.03 ± 0.96 (507)
Twelfth month	0.60 ± 0.75 (507)
AVVQ	
Pre-op	18.32 ± 5.24 (538)
First month	7.12 ± 2.38 (527)
Sixth month	4.63 ± 1.46 (507)
Twelfth month	4.61 ± 1.42 (507)

AVVQ: Aberdeen varicose vein questionnaire; VCSS: venous clinical severity score.

animal models, Almeida et al. published a two-year follow-up of the first human use of NBCA for the treatment of saphenous vein incompetence.⁶ In their study, 38 patients' follow-ups were completed, and they found the occlusion rate of 92.0% at the 24-month follow-up.

In a European Multicenter study on pulsed NBCA embolization of incompetent GSVs,¹⁵ 70 patients were treated and a one-year follow-up was completed in 60 (86%) patients. Occlusion rate was 94.3% at the six-month follow-up, with an improvement of VCSS from 4.3 ± 0.3 baseline to 1.13 ± 1.27 . Phlebitis occurred in six cases (8.7%). Morrison et al. compared radiofrequency ablation (RFA) with pulsed NBCA embolization (CAE) in a randomized VeClose trial. Two hundred twenty-two patients with symptomatic GSV incompetence were randomly assigned to receive either CAE ($n = 108$) or RFA ($n = 114$). Three-month closure rates were 99% for CAE and 96% for RFA.

Phlebitis rates were 20% for CAE and 14% for RFA. The authors reported that CAE was not found to be inferior to RFA for the treatment of GSV insufficiency at month 3 and was associated with less postprocedure ecchymosis.¹⁶

The second system is application of low-viscosity NBCA applied in a continuous way. Using this device and technique, three consecutive case series with considerable numbers of patients have been published from Turkey.^{17–19} In all these series, the occlusion rate was quite satisfactory, ranging between 97.2 and 100%. Bozkurt et al. compared NBCA (CAA, $n = 154$) and endovenous laser ablation (EVLA, $n = 156$) treatment in patients with GSV insufficiency in their prospective study. In this study, the authors especially mentioned that the NBCA viscosity was lower and polymerized in 5 s, and the application procedure was continuous. With the new NBCA and technique, 12-month follow-up closure rates were 95.8% for CAA and 92.2% for EVLA. VCSS scores improved from the baseline of 5.7 ± 2.3 to 0.6 ± 0.7 for CAA and from 5.7 ± 1.2 to 0.7 ± 0.5 for EVLA. Phlebitis rates were 4.5% for CAA and 7.7% for EVLA. The authors reported statistically significant differences for procedure time, pain during procedure, and ecchymosis in NBCA's favor.⁷

VenaBlock's NBCA gives a rapid polymerization reaction that can close the target vein in 5 s. Hence, continuous delivery is important: to catch up with the rapid polymerization time. Another important point is applying pressure over the vein following injection of NBCA. With this treatment, our aim is to stick the opposed endothelia of the vein together without causing thrombus formation as in thermal ablation. Because the polymerization time is rapid and injection of the glue is continuous, pressure should be applied immediately after injection of the NBCA.

The most important criteria in NBCA treatment of GSV are viscosity and procedure technique (pulsed or continuous). Current treatments show significant differences in procedure time and phlebitis. Both procedures have similar success rates with parallel benefits. In our study, the continuous technique was the procedural technique with a new brand system and resulted in similar results with current studies.^{7,17–19} We believe phlebitis occurring after an NBCA procedure relates to an excess amount of glue in a certain vein segment, causing reaction with blood and creating a thrombus-like formation. We call this phenomenon "phlebitis-like." Bozkurt, Yasim, and Calik also observed these phlebitis-like formations, which dissolve in a week. The right amount of pressure, at the right time and place, is necessary to stick endothelia walls together oppositely without leaving a thrombus formation inside. We believe that this was the reason why Bozkurt observed

a smaller phlebitis rate with continuous NBCA delivery compared with Almeida's and Morrison's reports. In our study, we observed less phlebitis than in the reported articles. We believe the guide light at the tip of the catheter may help where to apply manual pressure during glue application. Yet with continuous technique and low-viscosity NBCA, the phlebitis rate can be lowered after a learning curve without the aid of the guide light.

In our clinic, we have a substantial experience with thermal ablation techniques. Since the introduction of NBCA, we have used this technique routinely almost in all patients. In order to get statistically significant and plain results, this study focused on the GSV diameter under 15 mm. Our clinic experience supports that NBCA can be used in veins with GSV of 20 mm or larger like in the thermal ablation procedures. Although we report a single center experience in a substantial number of patients with GSV incompetence, this study has several limitations. Probably, one of the most important limitations of this study is the nature of a retrospective analysis with a short follow-up time. Since we just followed clinical routine, clinical follow-up on the third day, first month, sixth month, and 12th month may not give enough information about patients' symptoms. Since we just focused on the technique and closure rate of incompetent GSV, we did not analyze disappearance of varicosities, recurrence of varicose veins. In our general clinical experience, patients tend to stay away from surgical or additional procedures after NBCA procedure and want to wait for disappearance in their varicosities. Thus, we wait three to six months to see disappearance in varicosities, and then we performed phlebectomy or sclerotherapy as needed. Also, we did not analyze the overall cost of treatment including treatment cost and the cost related to return to work. This is a simple ambulatory procedure requiring local anesthesia which may be associated with early return to work or daily life.

Conclusions

After the 12-month follow-up of the study cohort, we conclude that the procedure appears to be feasible, safe, and efficient and that the great majority of incompetent GSVs can be treated with this technique. With the current studies about NBCA treatment of GSV, our study provides efficacy similar to current NBCA and endovenous ablation methods. Absence of tumescent anesthesia, short procedure time, and absence of the need for a compression stocking after treatment seemed appealing to patients. Initial findings are good; however, long-term results and comparative randomized trials are needed to confirm these findings.

Declaration of conflicting interests

The author(s) declared no potential conflicts of interest with respect to the research, authorship, and/or publication of this article.

Funding

The author(s) received no financial support for the research, authorship, and/or publication of this article.

ORCID iD

Turhan Yavuz  <http://orcid.org/0000-0002-0022-2856>

References

1. National Institute for Health and Care Excellence. *Varicose veins in the legs. The diagnosis and management of varicose veins*. National institute for Health and Care Excellence, <https://www.nice.org.uk/guidance/cg168> (2013, accessed September, 2017).
2. Hashimoto O, Miyazaki T, Hosokawa J, et al. A case of high-output heart failure caused by a femoral arteriovenous fistula after endovenous laser ablation treatment of the saphenous vein. *Phlebology* 2015; 30: 290–292.
3. Ostler AE, Holdstock JM, Harrison CC, et al. Arterial false aneurysm in the groin following endovenous laser ablation. *Phlebology* 2015; 30: 220–222.
4. Linfante I and Wakhloo AK. Brain aneurysms and arteriovenous malformations: advancements and emerging treatments in endovascular embolization. *Stroke* 2007; 38: 1411–1417.
5. Labenz J and Borsch G. Bleeding gastric and duodenal varicose veins: endoscopic embolisation using tissue adhesives. *Dtsch Med Wochenschr* 1992; 117: 1274–1277.
6. Almeida JJ, Javier JJ, Mackay EG, et al. Two-year follow-up of first human use of cyanoacrylate adhesive for treatment of saphenous vein incompetence. *Phlebology* 2015; 30: 397–404.
7. Bozkurt AK and Yilmaz MF. A prospective comparison of a new cyanoacrylate glue and laser ablation for the treatment of venous insufficiency. *Phlebology* 2016; 31: 106–113.
8. Staniszewska A, Tambyraja A, Afolabi E, et al. The Aberdeen varicose vein questionnaire, patient factors and referral for treatment. *EJVES* 2013; 46: 715–718.
9. Merchant RF, DePalma RG and Kabnick LK. Endovascular obliteration of saphenous reflux: a multicenter study. *J Vasc Surg* 2002; 35: 1190–1196.
10. Khilnani NM, Grassi CJ, Kundu S, et al. Multi-society consensus quality improvement guidelines for the treatment of lower extremity superficial venous insufficiency with endovenous thermal ablation from the Society of Interventional Radiology, Cardiovascular Interventional Radiological Society of Europe, American College of Phlebology, and Canadian Interventional Radiology Association. *J Vasc Interv Radiol* 2010; 21: 14–31.
11. Brothers MF, Kaufmann JC, Fox AJ, et al. N-butyl 2-cyanoacrylate substitute for IBCA in interventional

- neuroradiology: histopathologic and polymerization time studies. *Am J Neuroradiol* 1989; 10: 777–786.
12. Wang YM, Cheng LF and Li N. Histopathological study of vascular changes after intra-arterial and intravenous injection of N-butyl-2-cyanoacrylate. *Chin Dig Dis* 2006; 7: 175–179.
 13. Almeida JI, Min RJ, Raabe R, et al. Cyanoacrylate adhesive for the closure of truncal veins: 60-day swine model results. *Vasc Endovascular Surg* 2011; 45: 631–635.
 14. Kailasnath P and Chaloupka JC. Quantitative assessment of polymerization-binding mechanics of cyanoacrylates: model development and validation. *Am J Neuroradiol* 2002; 23: 772–778.
 15. Proebstle TM, Alm J, Dimitri S, et al. Twelve-month follow-up of the European multicenter study on cyanoacrylate embolization of incompetent great saphenous veins. *J Vasc Surg* 2014; 2: 105–106.
 16. Morrison N, Gibson K, McEnroe S, et al. Randomized trial comparing cyanoacrylate embolization and radiofrequency ablation for incompetent great saphenous veins (VeClose). *J Vasc Surg* 2015; 61: 985–994.
 17. Yasim A, Eroglu E, Bozoglan O, et al. A new non-tumescent endovenous ablation method for varicose vein treatment: early results of N-butyl cyanoacrylate (VariClose®). *Phlebology* 2017; 32(3): 194–199.
 18. Tok M, Tüydeş O, Yüksel A, et al. Early-term outcomes for treatment of saphenous vein insufficiency with N-butyl cyanoacrylate: a novel, Non-thermal, and non-tumescent percutaneous embolization technique. *HSF* 2016; 19: 118–122.
 19. Çalık ES, Arslan Ü, Ayaz F, et al. N-butyl cyanoacrylate in the treatment of venous insufficiency – the effect of embolisation with ablative polymerisation. *Vasa* 2016; 45: 241–246.